Lecture n. 10

Thyroid Surgery - Thyroid Cancer

Only in the last few years has our understanding of malignant thyroid tumors begun to take shape, and it cannot be said that we know everything we should. In any case, we have come a long way from the not too distant picturesque definitions and interpretations that have pervaded medical literature and teaching in recent years. Telling are the term "metastasizing adenoma" and the creative interpretations advocated by esteemed authors, some Italians included: for instance, equating the thyroid and endometrial parenchyma, and thus the metastasization of normal thyroid, "*thyreosis*", to endometriosis; or the other highly-regarded interpretation (perhaps still today) of normal thyroid tissue in the latero-cervical lymph nodes in the same manner as dysembryoplastic heterotopias. And still the conviction (cited to this day in some texts) of the benign nature of a "*papillary adenoma*", not to mention "*proliferating goiter*", "*metastasizing colloid goiter*", and so on.

The complexity of the current, more precise, classification of thyroid cancer makes it necessary - especially for teaching purposes - the breakdown of the subject into paragraphs, describing not only the varying anatomic-pathological features, but also and above all the different clinical pictures according to the various histological types.

As such, the topic will be tackled through subchapters following the above-mentioned format.

Single thyroid nodule

A single thyroid could very well be a cancer, but if it is observed and managed with an incorrect diagnostic work-up we cannot know *a priori*.

The nodule may be noticed by the patient, it may be found on palpation by the physician, or it may be detected by ultrasound (US) examination. Generally speaking, nodules that could prove to be malignant are hard and on US appear solid and often with intraparenchymal (color Doppler US) vascularization; hormone levels are not altered (except for calcitonin in the case of medullary carcinoma). It has already been pointed out (Lecture 9 on hyperthyroidisms) that low or even absent TSH levels should prompt consideration of the nodule as toxic. In this case, thyroid scintigraphy will reveal an exclusive uptake in the nodule, with absence of radionuclide uptake in the remaining thyroid parenchyma.

Patient history may prove important in the assessment of the nodule and its possible malignant nature. Here, risk factors are:

- previous radiation exposure;
- some authors claim age (prevalently between 40 and 70 years of age), but all - including pediatric and elderly age groups - can be affected;
- although the general rule of thumb holds that incidence of nodular thyroid disease is higher in females, it must be borne in mind that under the same conditions a nodule presenting the features described above will more likely be malignant in males;
- family history, especially with genetically predisposing diseases (medullary carcinoma, multiple endocrine neoplastic [MEN] syndromes, familial colon polyps, etc.).

It goes without saying that the presence of palpable lymph nodes of the neck yields pivotal diagnostic information.

The size of the nodule is an important parameter for purposes of assessment and relative behavior: indeed, nodules greater than 1 centimeter in diameter should be removed surgically and undergo perioperative histological examination.

Fine needle aspiration (FNA) biopsy - recommended by many in every case of a single nodule - becomes in my view compulsory in small nodules which may be treated conservatively and closely monitored, above all for any increases in size and the rate with which these occur. While the cytological features that can be discerned by this means guarantee its diagnostic accuracy for malignancy in most tumors, the same cannot be said for follicular forms, since it is not possible to distinguish benign (which are, moreover, more frequent) from malignant lesions. Histological sectioning is necessary in such cases to examine for the presence of vascular or capsular invasion, both hallmark features of follicular carcinoma.

In any event, while some groups believe that preoperative FNA can substitute perioperative cryostat sectioning in cases that are originally positive for cancer, many others - including us - hold that the not infrequent occurrence of false positives or negatives resulting from FNAB make perioperative histology indispensable.

General remarks on malignant thyroid lesions

According to different statistical sources, thyroid cancer represents from less than 1% to 1.5% of all malignant tumors, with an incidence that varies from 10 to 40 new cases per million per year depending on geographic area (a factor which impacts on all thyroid disorders). It is estimated that the disease accounts for approximately 6 deaths/million each year.

Most (90-95%) of these lesions belong to the so-called class of differentiated tumors, i.e., papillary carcinoma, its follicular variant, the classic follicular form and its Hürtle cell variant.

From an etiological - pathogenetic standpoint, the last section on the single nodule listed some of the factors that putatively constitute a risk. Nevertheless, numerous studies have implicated other situations that could have an etiological impact or could at least promote the onset of these diseases. Many of these, as already mentioned, are likely linked to environmental and/or geographic conditions, namely, hyperthyroidism, iodine deficiencies, and, by contrast, for some areas and for some tumor forms, even iodine prophylaxis, and still others that, in my view, are not deserving of further comment. Indeed, in my opinion most of these for the study conditions adopted lack sufficient and reliable evidence.

On the other hand, worthy of consideration is the role of the so-called activating oncogenes, which are increasingly the focus of intense study and which, in some cases, the specific pathogenetic role in certain tumors has been demonstrated.

The same holds true for neoplastic thyroid disease, with many ongoing studies having already shown intriguing results.

It appears that at least 40% of these tumors have one or more mutations of the RAS gene (codifying the transduction signal protein G) and recent claims seem to be upheld. These mutations seemingly have a lower incidence in populations residing in areas where iodine intake is sufficient, a finding occurring together with other genetic factors in such areas (availability of iodine). They are more frequent in papillary carcinomas induced by radiation, etc.

Likewise, the RET proto-oncogene (a receptor tyrosine-kinase on the cell membrane) seems to play a role in thyroid cancer, it also presenting broad geographic variations. It has been implicated in medullary thyroid carcinoma, as well as in other tumors like neuroblastoma, pheochromocytoma and other stromal forms. In papillary thyroid carcinoma, too, the role of this proto-oncogene has been demonstrated, and it is considered to be a pathogenetic component associated with other mutations in MEN syndromes.

Discussion of this topic lies beyond the scope this chapter. Nevertheless, it is worthwhile to underscore the timeliness and importance of the issue, viewing it as a precursor of further progress into our understanding of the pathogenesis and management of many tumors, much the same as already transpires for other neoplastic lesions occurring in different sites and of varying histotype.

Papillary carcinoma

This is the most frequent among the differentiated tumors of the thyroid, occurring at a rate ranging from 50 to 70% depending on the reporting series. The frequency of this tumor has progressively grown over the past 10-15 years, as has that of all differentiated thyroid lesions.

Beyond the attention paid to these neoplasms - which has increased during this time span as has our greater understanding of it - it is plausible that this incidence has been paralleled by an increase in specific oncogenic stimuli due to varying environmental conditions, e.g., air pollution, chemical and dietary agents, radiation exposure, etc.. In particular, the action of this latter is well-known, especially for papillary carcinoma. As such, we have witnessed the onset of the disorder, generally after 5-10 years, in subjects exposed to external radiation sources. This is the case of patients, usually children, who decades earlier had undergone radiotherapy for diseases such as lymphatic hyperplasia (a.k.a. "*lymphatism*"), thymic hyperplasia and still others. In adults with Hodgkin's disease or other neoplastic lesions of the neck, thyroid carcinoma usually of the differentiated papillary type developed with a surprisingly high frequency and over varying time spans. Finally, the neoplastic consequences (again frequent in children) of exposure to radioactive fallout from nuclear accidents are all too well-known. Here again, papillary carcinoma represents the most frequent lesion.

From an anatomic-pathological standpoint, this lesion is archetypical of a differentiated tumor. In fact, for most pathologists and oncologists all differentiated thyroid tumors - including follicular carcinoma - derive from the papillary form, and are thus one in the same. This hypothesis has numerous advocates and therefore deserves mention. However, for purposes of clinical classification and for mere clarity of exposition, the two forms of papillary and follicular carcinoma should be distinguished.

Macroscopically the lesion may present with different size, its diameter ranging from a few millimeters to many centimeters. Generally speaking the neoplastic forms of *microcarcinoma* and *occult carcinoma* belong to this category.

There is little consensus on the two terms, but they are widely used to describe frequent manifestations of malignant thyroid disease, often synonymously for very small lesions that evade clinical and instrumental detection. In my opinion, however, they constitute two different clinical conditions. The only parameter that holds true for both is the small size, i.e., a maximum diameter of less than a centimeter, and most often less than 5 millimeters.

A microcarcinoma, however, is generally a lesion with features of development, presenting most often with latero-cervical tumefaction, signs of lymph node metastasis, and normally ipsilateral with respect to small primitive neoplasms **(see video)**.

As a rule of thumb occult carcinoma does not present growth features. It, too, usually has a papillary structure: it is often encapsulated, at times of a sclerosing or cystic type. Autopsy studies have revealed a high detection rate of the lesion, even greater than 30%, clearly having nothing to do with the cause of death (the autopsy

incidence of thyroid nodules is above 50%). It is found during post-operative histopathological examination in 10% of cases of multinodular goiter. Even after conservative thyroidectomy in these cases the lesion does not give rise to distant sequelae (as confirmed by our experience, as well).

Papillary carcinoma is a solid tumor with a firm but not wood-like texture. It is generally found in the thyroid parenchyma, at times emerging from under the capsule of the gland. Only in very advanced cases, rare as they are, does the lesion become extracapsular. The margins of the lesion are whitish, sometimes rosé in color, and calcifications, cystic changes and hemorrhagic and/or necrotic areas may be present.

Histologically, the papillae consist of epithelial cells surrounding a fibrovascular stalk. Areas of follicular differentiation are not uncommon. Nuclei may have a clear, ground-glass, appearance, at times with overlapping of elements (pseudoinclusions) and a raised nucleus/cytoplasm ratio. The presence of psammoma bodies is a histological hallmark of the diagnosis of papillary carcinoma. A number of variants - namely insular, columnar, tall cell and sclerosing- are known. It is still unclear whether these forms are any more aggressive. The term follicular variant is used when follicular elements outnumber papillary formations. Lymphocyte infiltration is not infrequent.

Papillary carcinoma may be multicentric and preferentially metastasizes to regional lymph nodes. Distant metastases are improbable and the lesion rarely shows features of extraglandular infiltration.

From a clinical standpoint

A palpable nodule in the front of the neck that can be traced to the thyroid, single and solid on US examination, above all in males, and even more so if in pediatric age or young, must be considered – in lieu of confuting evidence – a malignant neoplastic lesion. In all likelihood it is a papillary carcinoma, and FNA will confirm suspicions. In such cases this procedure is pathognomonic and thus constitutes a compulsory diagnostic tool. The individual cyto-morphology allows identifying the lesion's papillary nature. Diagnosis is based, beyond the above-mentioned cellular and nuclear features, also on findings of clear, large, empty nuclei with a characteristic Orphan Annie-eye appearance and with the inclusion of elements and nuclear grooves.

Another frequent sign of disease at presentation is the large mass affecting one thyroid lobe, which is often accompanied by lateral cervical tumefaction, i.e., an expression of metastatic lymphadenopathy.

Finally, it is not uncommon to witness the appearance of laterocervical lymphadenopathies, which on FNA will be shown to be papillary thyroid carcinoma metastases, without findings at physical examination of any palpable alterations occurring in the gland. In these cases, not even US is able to detect the responsible microcarcinoma, and only seriated histological analyses will allow recognition of the lesion.

Treatment is surgical and entails total thyroidectomy, with so-called "functional" lymphadenectomy, i.e., limited to regional nodes (recurrent, thyroid-thymic, jugular, lateral cervical), only if metastatic. Without such clear evidence,

selective lymph node removal ("*berry picking*") in the different sites with perioperative histological analysis is sufficient. The same holds true preliminarily also for the further diagnostic confirmation of primary tumors.

Once removed the entire thyroid must undergo histological analysis, not so much to define the tissue features of the tumor, but rather to identify possible neoplastic foci beyond the primary tumor (possibly in the contralateral lobe, as well).

Total thyroidectomy, which constitutes our usual treatment approach for differentiated (not only papillary) thyroid carcinoma, is grounded on the following:

- treatment of possible multifocality;
- attempt to create a "*clean slate*" for the nuclear medicine specialist, at least to submit the patient for treatment with the least possible mount of residual thyroid thereby allowing lower doses of radionuclides to achieve ablation;
- to provide for safe radio-metabolic monitoring (to detect possible metastatic foci in hypothyroidism);
- to allow selective radio-nuclear therapy of possible disease recurrence;
- to take advantage of serum thyroglobulin measurements during follow up (only relapsing or metastatic neoplastic thyroid tissue produces thyroglobulin).

For these very reasons we disagree with authors who opt for a conservative thyroidectomy to treat differentiated carcinoma. At the same time, this conviction is not steadfast, since our own experience shows at times if nothing else the relatively benign nature of these tumors. First of all, as was already pointed out above, years ago surgeons acknowledged the existence of benign thyroid adenomas with a papillary structure, and surgical treatment entailed only the so-called enucleation-resection of the nodule. Some of our patients treated this way are still being followed by us, and after no less than 30 years none shows any sign of cancer.

Still another case deserving of some reflection: a 30-year-old woman presenting with a small nodule less than a centimeter in diameter palpable at the isthmus. Despite advice to the contrary, the patient demanded that the nodule - only 5 mm in diameter - be ablated. A formation with a papillary structure was removed via an isthmectomy. The patient recovered fully without consequences even at long term. This anecdotal experience dovetails with our conservative approach towards occult carcinomas in multinodular goiters, as well as with results of prognostic data. Indeed, most cases of papillary carcinoma carry an excellent prognosis , which for the most favorable stages reaches a 95% 10 year survival rate. Nevertheless, such a favorable prognosis may be jeopardized by a myriad of factors bearing on the patient's clinical picture and on anatomic pathological staging. Thus, the importance to identify at-risk groups of patients through specifically designed staging methods, the best-known of which are:

- **AMES** (Age, Metastasis, Extent of disease, Size), developed by Cady e Coll.(1979-1988) of the Lahey Clinic,
- **AGES** (Age, histologic Grade, Extent of disease and distant metastasis, Size) developed by Hay e Coll.(1987) of the Mayo Clinic,
- **TNM** (Tumor, Node, Metastasis) staging system (1987) of the International Union Against Cancer;

- The International Staging System (1987) of the American Joint Committee on Cancer (AJCC);
- The version of this last system updated in 2003.

It seems that age at presentation is the most important prognostic factor: if diagnosed at under 40 years of age, long-term survival is quite possible.

Analysis of the survival curves of our patients confirms all of the aggravating factors considered in the above-mentioned prognostic methods (age, tumor size, stage, distant metastasis). (*)

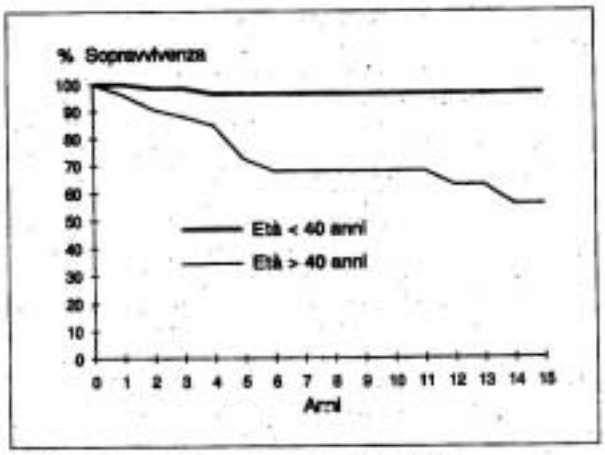

Fig. 1. — Curva di sopravvivenza per età. p<0,005.

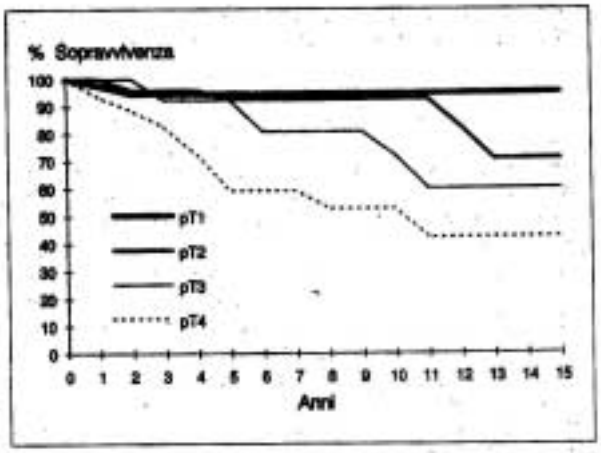

Fig. 3. — Curva di sopravvivenza per pT. pT1 vs pT2 ns; pT2 vs pT3 ns; pT3 vs pT4 p<0,001; pT1 vs pT3 ns; pT2 vs pT4 p<0,001; pT1 vs pT4 p<0,001.

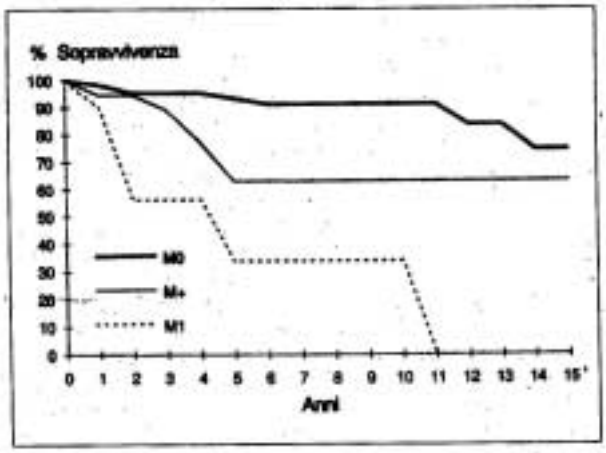

Fig. 2. — Curva di sopravvivenza per M. M0=non metastasi, M+ =metastasi dopo l'intervento, M1 = metastasi già prima dell'intervento. M0 vs M+ p<0,05.

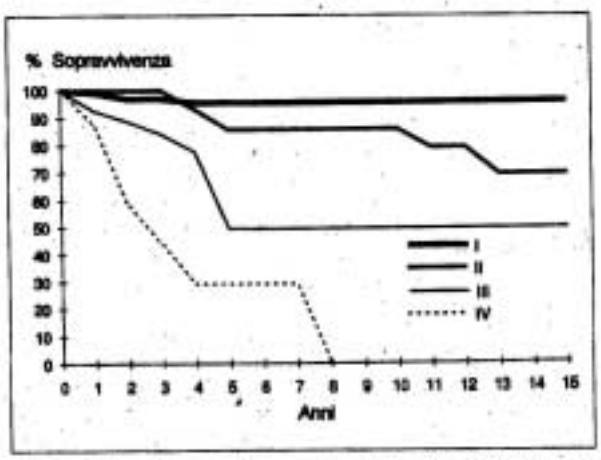

Fig. 4. — Curva di sopravvivenza per stadio. I vs II p<0,05; II vs III p<0,001; I vs III p<0,01.

(*) (From Mattioli FP., Torre G.C. and Co-workers - *Il trattamento del cancro differenziato della tiroide. Chirurgia 1993;6:348-355*)

Follicular Carcinoma

Follicular carcinoma together with papillary carcinoma constitute make up the well-differentiated thyroid carcinomas. The two share a number of features, which were dealt with above and on which we will not dwell. Here we will discuss the elements that distinguish the follicular form. Compared to papillary carcinoma and other thyroid malignancies, follicular carcinoma is relatively rare (5 to 10% of cases with thyroid cancer). The disease, particularly the Hürtle cell variant, typically affects patients at a more advanced age, and appears to be more frequent in regions with low dietary iodine.

From an anatomical-pathological standpoint the lesion may present as generally single masses of different sizes. Most of these tumors are well-encapsulated, while others may show a tendency to invade and/or infiltrate surrounding tissues and structures.

Microscopically the tumor may simulate normal follicular architecture and function, which explains the secretion of thyroglobulin by metastases (see postsurgical thyroglobulin monitoring), not to mention the already mentioned dated interpretations of the detection of "normal" thyroid in heterotopic sites. But the histological structure may vary, exhibiting trabecular features with solid areas of growth that may become seriously irregular. While lymphatic vessels invasion is rare - from which the notion about the rarity compared to papillary carcinoma of lymph node metastasis arises - blood vessels invasion is common, which underlies the observation of increased metastasis via bloodstream routes (lung, bone, brain and other solid organs). The capsule - with which the tumor is often endowed - may be infiltrated or even breached. These two attributes - vascular invasion and capsular infiltration - are often the only features that can histologically differentiate follicular carcinoma from follicular adenoma, which would otherwise be indistinguishable in cases of cancer with pseudo-normal structure.

From a clinical standpoint, in its non-invasive form, follicular carcinoma behaves nearly identically to papillary carcinoma. Differences arise with the invasive forms, with the involvement of adjacent structures (recurrent nerves, trachea, etc.) and the appearance of metastasis, which is rather uncommon in regional lymph nodes (fewer than 5% of cases), but more often occurs distantly. It goes without saying that both the direct involvement of nearby structures and the metastatic involvement of distant structures will be responsible for the related specific symptoms.

Follicular carcinoma tends to strike at an older age, carrying with it a progressively poorer prognosis as age advances. In any event, this malignancy has worse prognosis than papillary carcinoma. The major clinical problem lies in the recognition of the malignant nature of a single nodule: at present FNA can reveal only the presence of follicular elements, but no current cytological tenet allows discerning its true nature. And this is exactly the premise underpinning the choice of surgical intervention in the attempt to identify traits of malignancy (vascular invasion and/or capsular infiltration). Because histological analysis on frozen sections often fails to yield such data, the limited ablation of the nodule is inadvisable so as not to

deprive the pathologist, during subsequent, more detailed, examination, of important information that can allow formulating an accurate diagnosis of cancer. Otherwise, re-operation - and with it the greater risk that it entails (i.e., inadvertent damage to the parathyroid glands and recurrent laryngeal nerve injury) - becomes necessary. It is thus wise to perform at least a lobectomy, resorting only at a later stage to the removal of the residual lobe that was left untouched by the previous surgery and thereby limiting undesirable consequences.

From what has been said it is inferable that once the diagnosis is confirmed the surgical treatment of choice becomes - compulsorily, I would say - total thyroidectomy, sparing satellite lymph nodes and foregoing exploratory "berry picking" procedures (except for rare macroscopic evidence).

The rationale for total thyroidectomy already proposed for papillary carcinoma, namely and above all to facilitate subsequent radio-metabolic treatment approaches, holds true for follicular carcinoma, as well. In this sense, the greater similarity of this neoplastic cell to normal thyrocytes makes radionuclide therapy all the more effective.

In this regard, a case from my experience is very instructive: a 70-year-old patient, who 10 years earlier in a hospital in a different city had undergone surgery for the removal of a thyroid nodule diagnosed as benign follicular adenoma. The patient came under our care with a picture of miliariform lung, whose micronodules showed radionuclide uptake and were thus judged to be metastatic of thyroid origin; the gland, however, showed no apparent signs of disease. Together with endocrinologists and nuclear medicine specialists a total thyroidectomy was scheduled, on the one hand to check the gland's condition, but above all to leave the metastatic tissue as the only target of radionuclide uptake. The complete and accurate histological analysis of the glandular parenchyma revealed no alterations, and subsequent radio-metabolic therapy performed under conditions of hypothyroidism (intense thyrotropinic stimulation on metastatic tissue) induced complete and definitive disappearance of metastatic localizations in the lungs (beyond ruling out the presence of other metastatic foci).

This case confirms the following assumptions:

- The difficulty to recognize the malignant nature of a follicular tumor;
- The disease's slow progression;
- The efficacy of radio-metabolic therapy

The subtype presenting oxyphillic and oncocytic cells, Hürtle cell carcinoma, does not differ meaningfully from what has been described above. Some authors believe that this variant is more frequent in advanced age and that it is more aggressive.

Medullary carcinoma

Medullary thyroid carcinoma (MTC) does not belong to the thyroid histotype, but arises from parafollicular C cells that produce calcitonin. These cells derive from

the neural crest and form part of the Amine Precursor Uptake and Decarboxylation (**APUD**) system. As such, this malignancy belongs to the group of neuroendocrine tumors. MTC cells also produce a series of other substances , the most important of which for diagnostic purposes is carcinoembryonic antigen (CEA). The lesion accounts for 5-10% of all thyroid malignancies and presents in two forms, sporadic and hereditary.

The former may be detected as a palpable mass or as a rise in serum calcitonin. In the first case FNA will easily reveal the cytology of the lesion, while in the second US may be able to detect a nodule that is usually single or solid.

The latter may bear familial characteristics and be an expression of a Multiple Endocrine Neoplasia (**MEN**):
- MEN 2A = MTC + adrenal pheochromocytoma + parathyroid hyperplasia
- MEN 2B = MTC + adrenal pheochromocytoma + multiple neuromas and ganglioneuromas.

In these cases the lesion may be multifocal, often involving both thyroid lobes and showing an aggressive and infiltrating propensity. These variants are inherited via an autosomal dominant mutation.

MTC is more aggressive than differentiated thyroid malignancies and is multifocal in at least 20% of sporadic cases and in 90% of familial cases. Lymph node metastases are present in more than 50% of cases overall.

From an anatomical-pathological standpoint MTC presents as a mass of varying volume, well-circumscribed or diffused-infiltrating, and deep yellow in color. Microscopically MTC contains epithelial-like cells, gathered together in trabeculae with amyloid-rich capsules. Variations include different histological types (papillary, glandular, small-, giant- or spindle-cell).

Treatment of MTC is total thyroidectomy with lymphadenectomy of the central compartment; extension of intervention to lateral lymph node structures depends on the presence of enlarged nodes detected by US and/or palpation. A “berry picking” procedure of all regional areas may at times prove useful. Some authors recommend thyroidectomy if hypercalcitoninemia and C cell hyperplasia are found even without evidence of neoplastic growth. For the hereditary forms (familial MEN 2A and MTC) preventive thyroidectomy is advised by many for at-risk family members inheriting the RET gene mutation.

Follow up of patients in whom MTC has been treated includes periodic monitoring of serum calcitonin, when necessary with pentagastrin or calcium stimulation.

Prognosis is very poor if the malignancy is or becomes metastatic. The results achieved with existing radio- and chemotherapy treatment protocols are still unclear. Some gene therapy trials (targeted therapy) are ongoing, which could yield new treatment prospects for this and other oncological conditions.

Anaplastic carcinoma

Compared to other thyroid tumors, anaplastic carcinoma is fortunately rare; however, it is an extremely serious malignancy. Incidence seems to have declined in recent years, accounting for no more than 1.1% of all thyroid carcinomas. This finding likely ensues from the increased practice of iodine prophylaxis and improvements in the treatment of non-tumoral thyroid disease. In fact, anaplastic carcinoma, which typically presents at ages above 70, often arises on a longstanding and improperly treated benign hyperplastic goiter. Onset in normal thyroid is, nonetheless, not uncommon.

The malignancy can present in a variety of ways. Patients may notice a sudden increase in the size and consistency of a pre-existing but stable and asymptomatic goiter; this condition can be accompanied by pain, dysphonia, dyspnea and sometimes dysphagia. Alternatively, the disease manifests itself with the appearance of these compressive symptoms in patients without previous thyroid disease. At physical examination the gland is enlarged and has a wood-like texture, often giving the sensation of a plastron.

Ultrasound examination confirms the replacement of the gland by solid, non-circumscribed, tissue that often exceeds the limits of the thyroid gland and involves the nearest structures; an increase in the volume of cervical lymph nodes is frequent and rapid. The tumor generally presents as a whitish-colored mass, hard and brittle, rarely contained within and more often exceeding the thyroid capsule, to the extent that it infiltrates and replaces structures with which it comes into contact (namely, the inferior recurrent laryngeal nerves, the trachea, large neck vessels and the esophagus).

Histologically, the lesion is usually made up of giant cells with distinct pleiomorphism, with hyperchromatic, often multiple, strangely shaped and highly mitotic, nuclei. The variants are numerous and imaginative: the squamoid form resembles spindle-cell carcinoma, even forming pearls; the spindle-cell variant imitates sarcoma, and when rich in collagenic and fascicular stroma, it looks like a fibrosarcoma. The tumor often manifests inflammatory features and areas of necrosis, where large cells that may have a reactive function bear a resemblance to osteoclasts: this picture recalls a malignant fibro-histiocytoma or, if highly vascularized, takes on a hemangioendotheliomatosis-like structure. These cytological aspects validate FNA diagnostics.

Because it is well-known that no treatment, surgical or otherwise, is able to stop disease progression, extreme care must be taken when adopting a therapeutic strategy. Attempts to understand the disease process should be made: standard radiology and CT scan can reveal the primary lesion's extension and possible distant manifestations. In many cases palliative surgery is the only prospect, namely tracheostomy, nutritional stomas, etc., in order to prepare the patient for alternative therapies (radio- and chemotherapy). If the tumor seems to be limited to the thyroid gland or to immediately adjacent structures, total thyroidectomy with

lymphadenectomy may exceptionally be resorted to in the attempt to improve survival and in quality of life.

The pessimism surrounding anaplastic thyroid carcinoma is grounded on surgical and other therapeutic outcomes registered by all patient series. Most subjects undergoing what is deemed aggressive thyroidectomy do not survive more than six months: longer survival is an exceptional rarity. Death occurs following local relapse or distant metastases. Our own patient series (Surgical Clinic of the University of Genoa) corroborate these findings.

The last operation I performed for anaplastic thyroid carcinoma is emblematic. A 70-year-old man, vigorous and athletic despite his age had for an unknown period of time been affected by a hardly visible and asymptomatic goiter. He suddenly became aphonic, which was treated for some time as laryngitis. When he came under my care the front region of neck was occupied by what seemed to be a hard plate; laryngoscopy showed right vocal cord paralysis, while US revealed a solid mass with unknown margins in the right thyroid lobe and enlarged lymph nodes. Radiological examination revealed no other visible alterations. Total thyroidectomy with lymphadenectomy of the central compartment was performed: tumor (anaplastic carcinoma on frozen section) presented extrathyroid expansion to the right, with the right recurrent laryngeal nerve embedded in the tumoral mass and no longer recognizable. Surgical intervention was aggressive. The patient was released early and soon underwent radio- and chemotherapy. Brain metastasis appearing three months later led to death.

The Lecture on benign goiter emphasized this feared consequence of not removing the goiter in elderly patients, which could expose to transformation of the condition into anaplastic carcinoma.

In conclusion, it should be borne in mind that thyroid cancer comprises two, quite different, extremes: on the one hand differentiated carcinoma, like papillary carcinoma, so "un" malignant as to mimic a benign tumor; on the other, a malignancy so aggressive that no currently available therapeutic means can tame it.

Pictures

Papillary thyroid Carcinoma

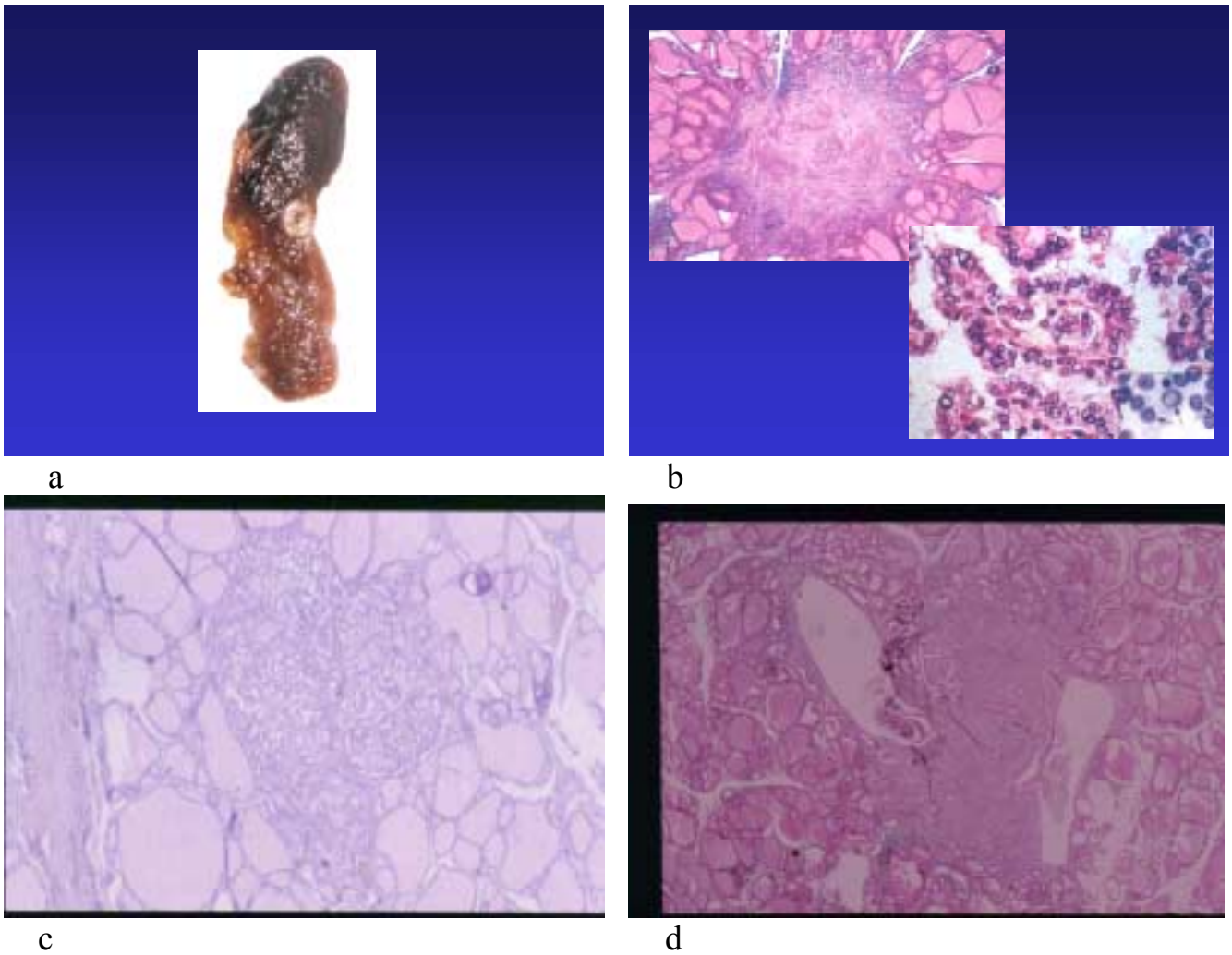

Fig. 1-Microcarcinoma. papillary structure: in b) empty "Orphan Annie" features are noticeable.

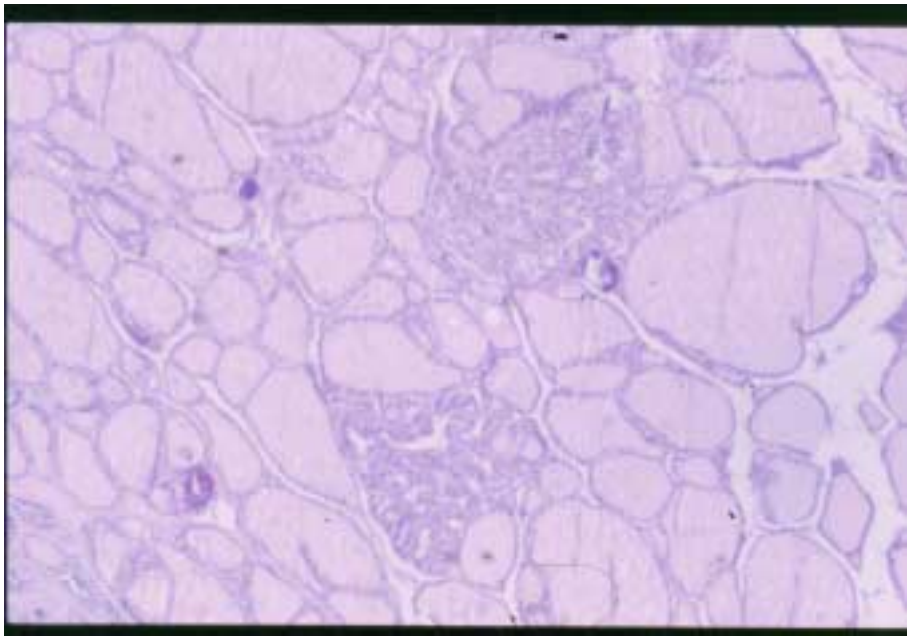

Fig. 2 - Multifocal papillary microcarcinoma

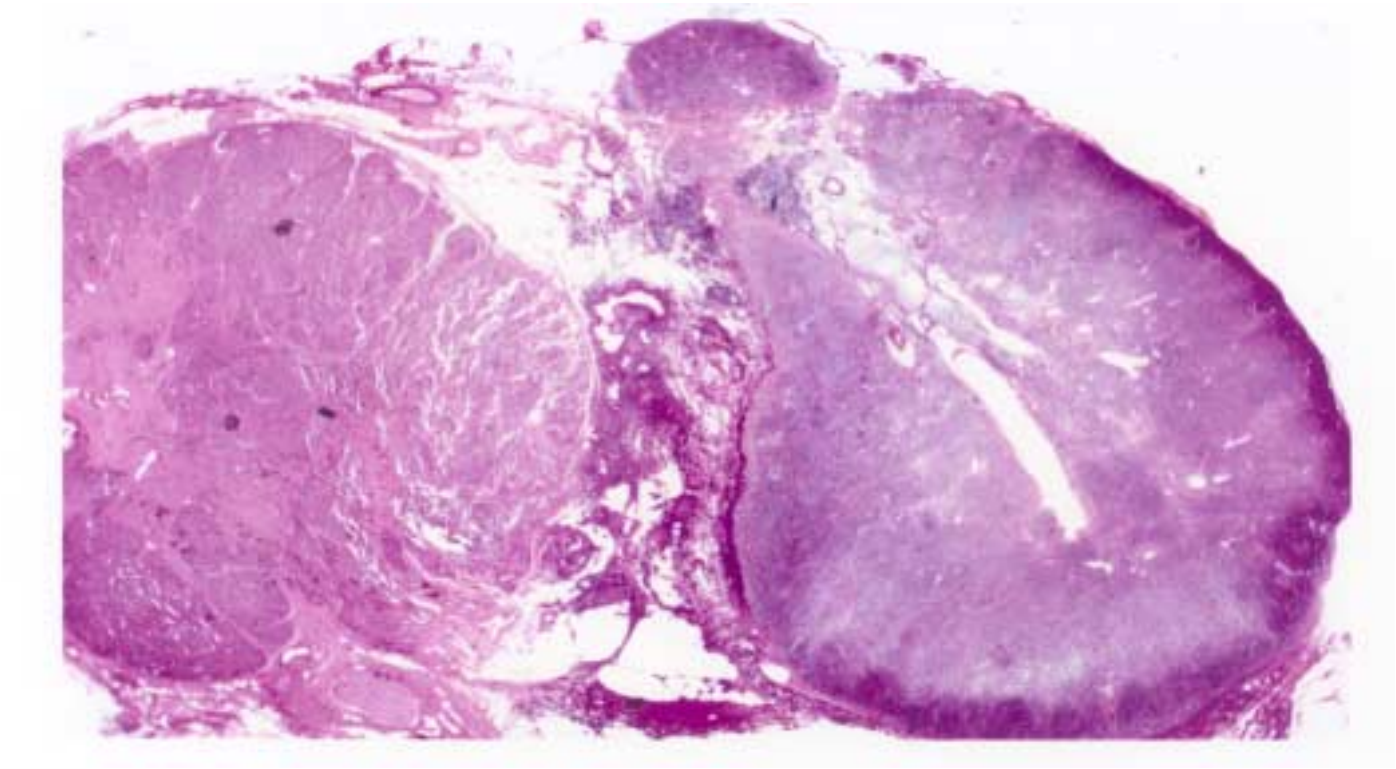

Fig. 3 - Lymph node metastasis from papillary carcinoma

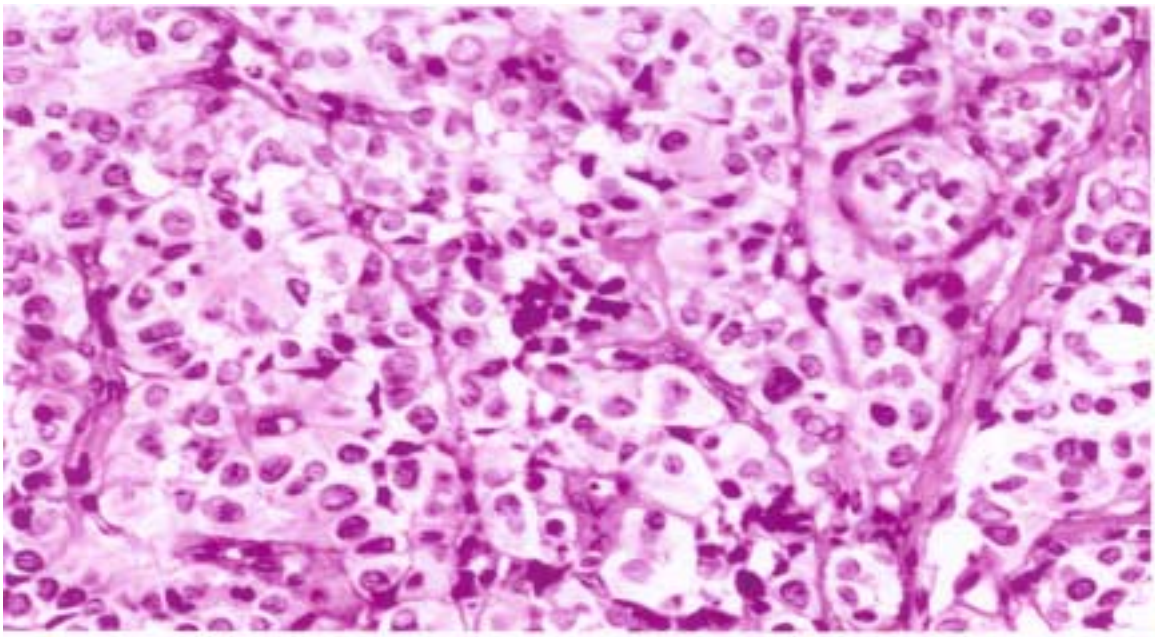

Fig. 4 - The papillary carcinoma structure is evident in the lymph node metastases.

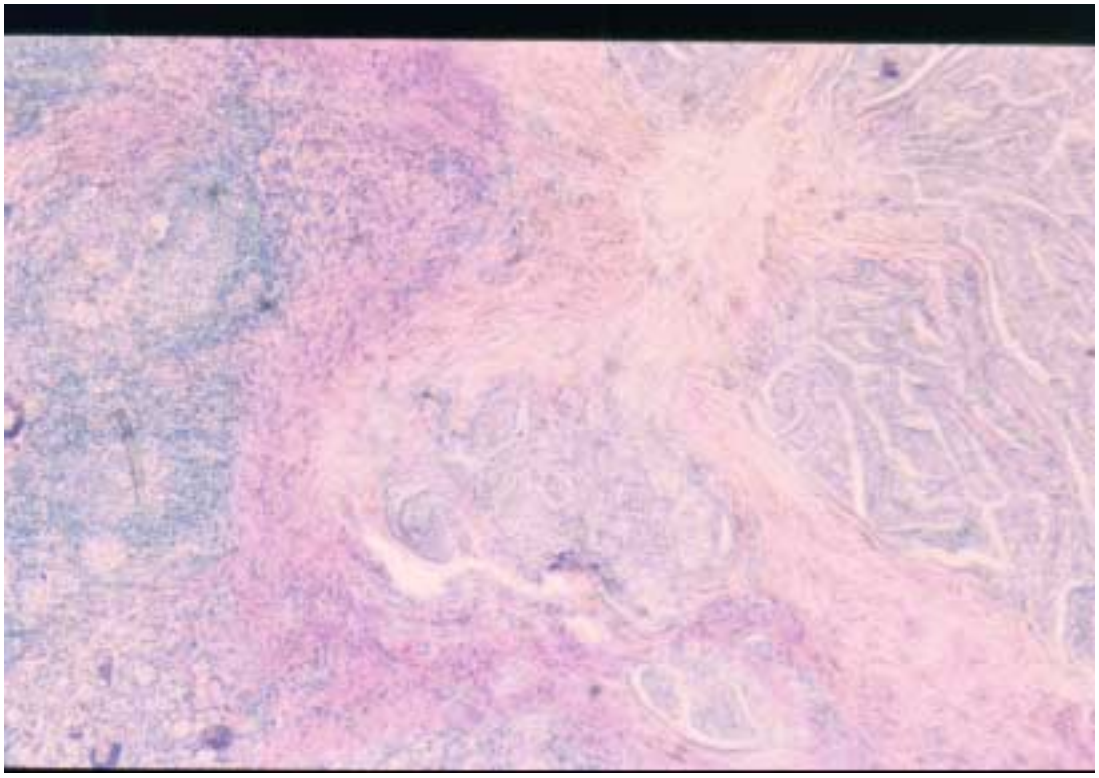

Fig. 5 - Papillary carcinoma with diffuse fibro-sclerotic component and lymphocyte infiltrates.

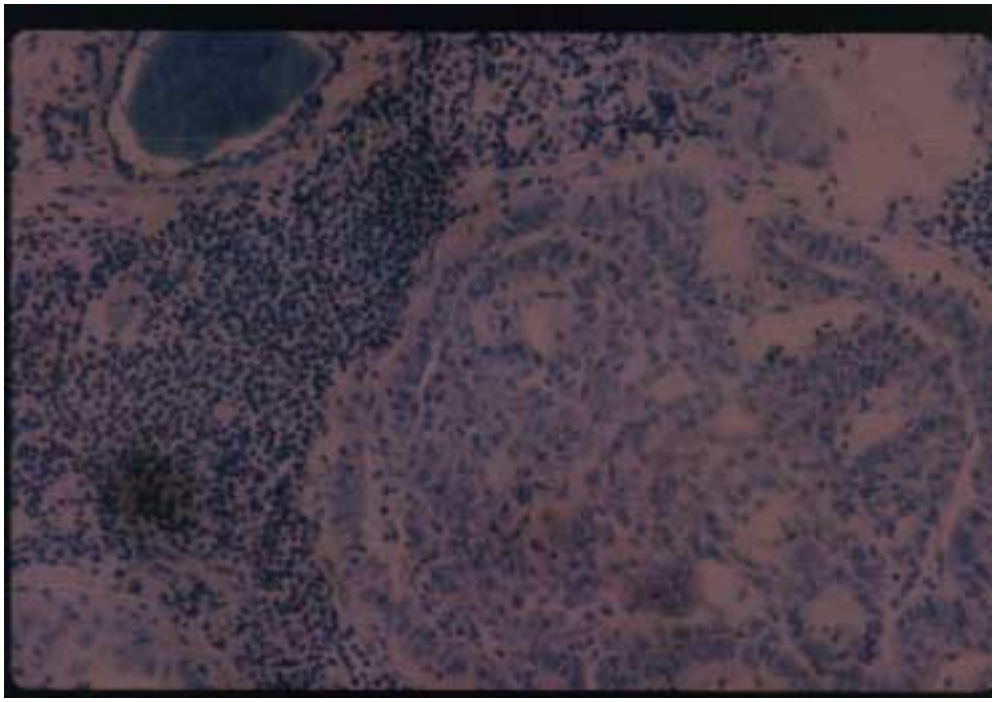

Fig. 6 - Papillary carcinoma with dense lymphocyte infiltrates.

Treatment of papillary carcinoma with intense lymph node metastases

Fig. 7 - The tumor

Fig. 8 - Extrication of the malignancy

a

b

Fig. 9 - a) the tumor is infiltrating and seems to be contiguous with lateral cervical lymph nodes; b) medial shift of the sternocleidomastoid muscle: intense lymph node metastasis is evident.

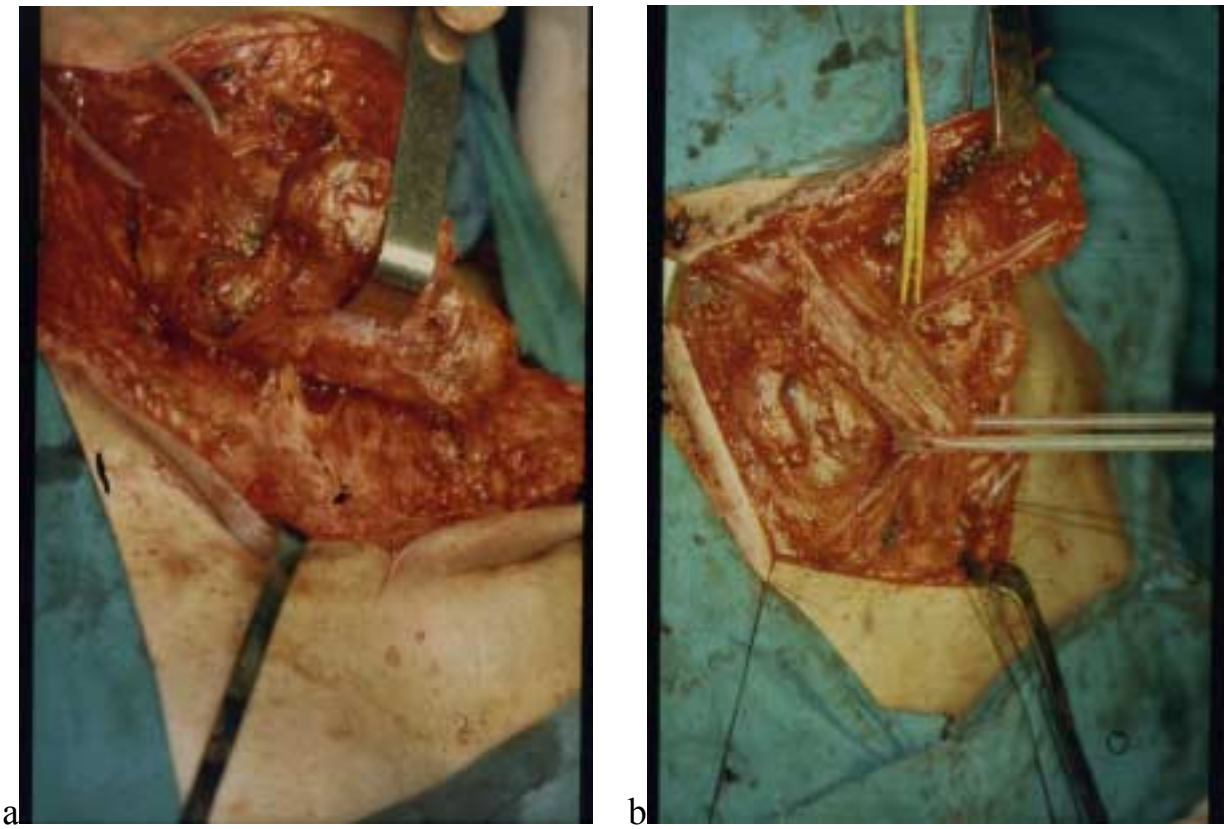

Fig. 10 - a) contiguity with lymph nodes is visible; b) the lymph nodes of the vascular bundle are approached once the glandular and lymph node neoplastic mass is mobilized.

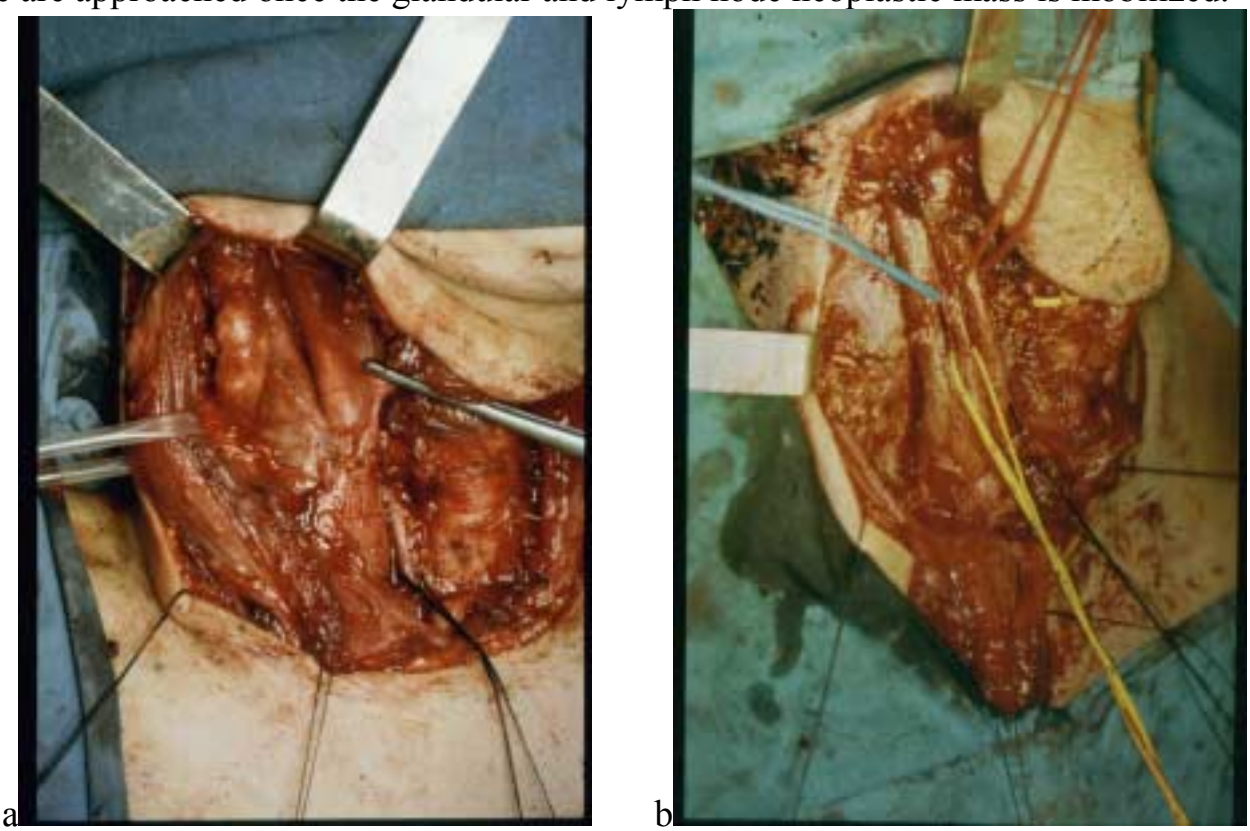

Fig.11-a) metastatic jugular chain after total thyroidectomy (note at the right the trachea and the recurrent laryngeal nerve); b) the nervous-vascular bundle following lymphadenectomy.

Fig. 12 - The anatomical-surgical picture at the end of the operation.

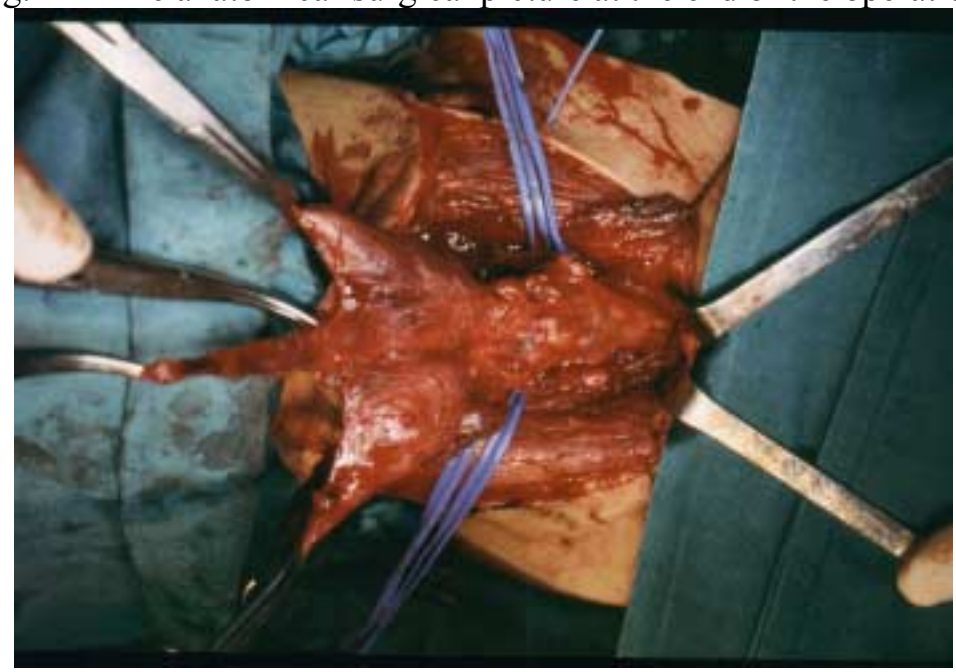

Fig. 13 - Another case with thyroid-thymic expansion. The entire gland was mobilized and is still held back by the tumor mediastinal component.

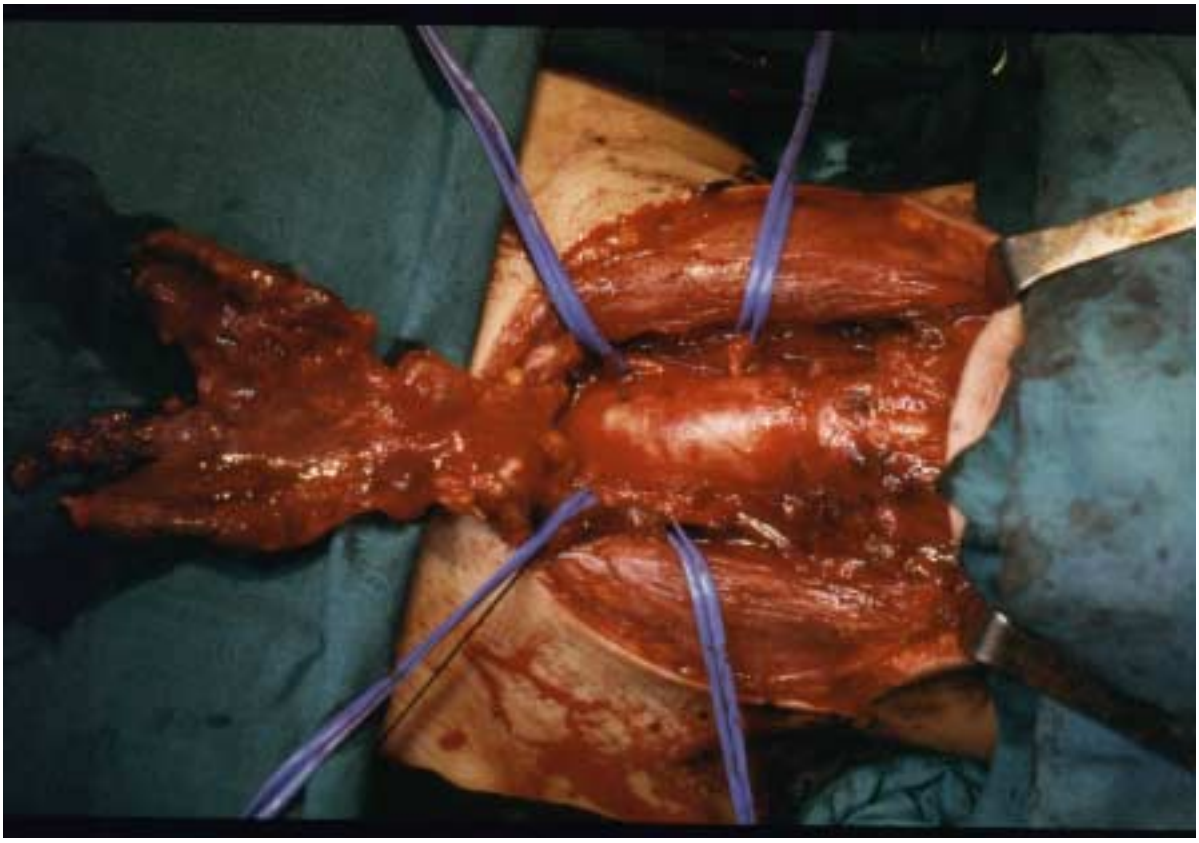

Fig. 14 - Downward removal of tumor. Loops indicate the recurrent nerves and inferior thyroid arteries.

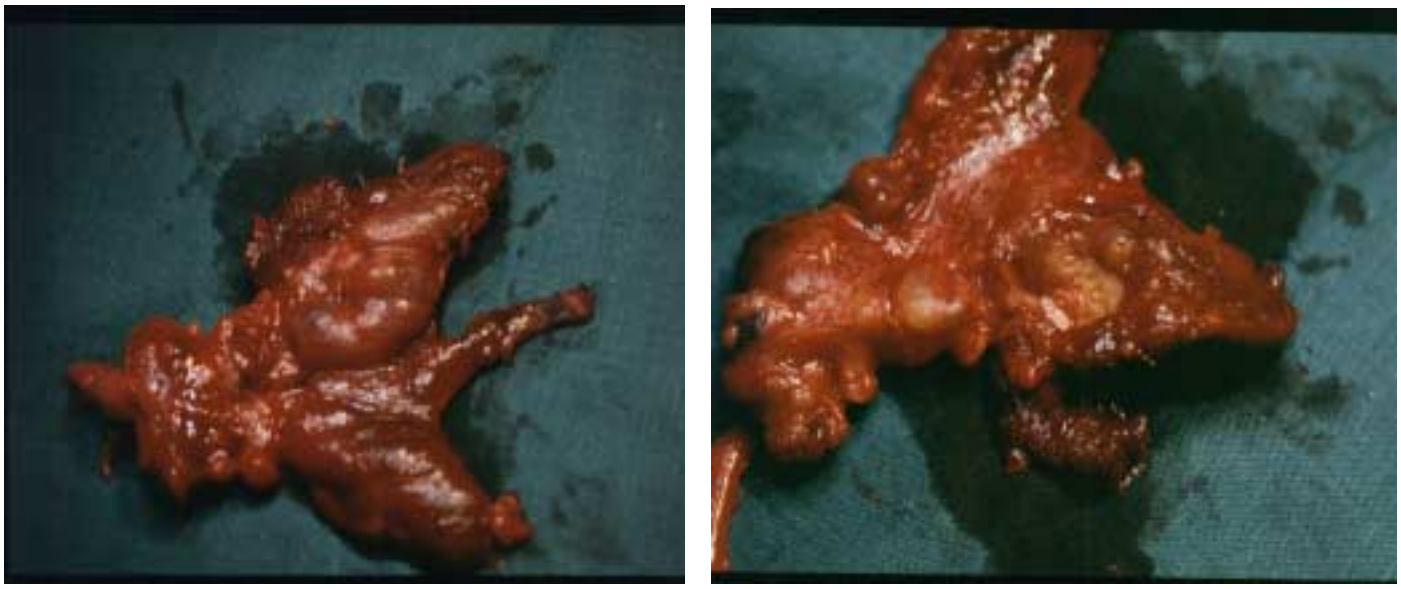

Fig. 15 - The surgical specimen

Follicular thyroid carcinoma

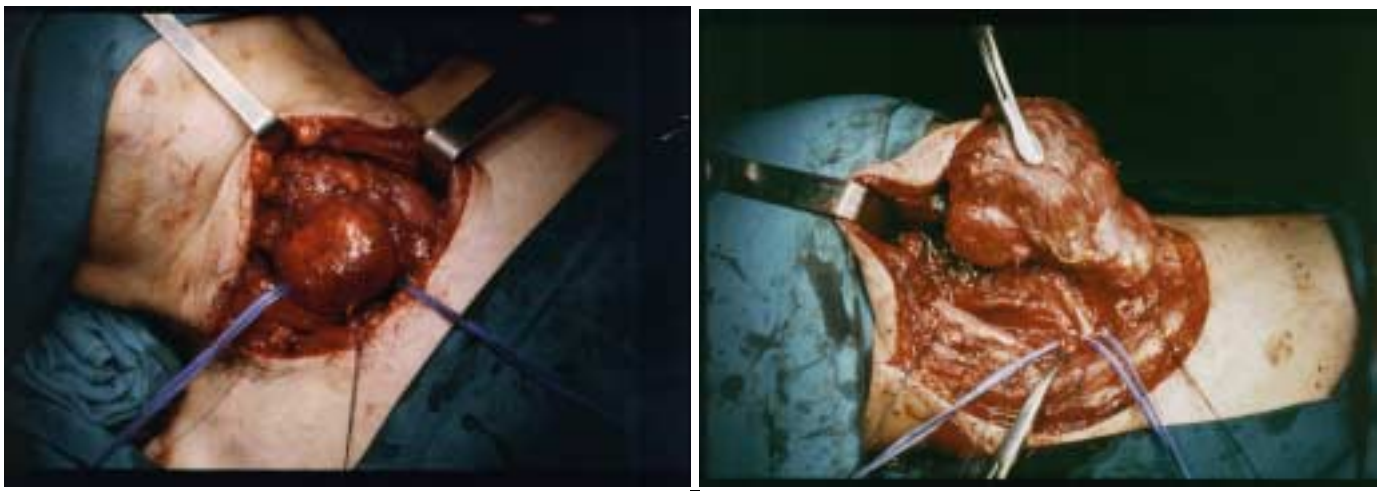

a b

Fig. 16 - Follicular carcinoma of the right lobe. In b) mobilization of the lobe; the loop passes under recurrent laryngeal nerve.

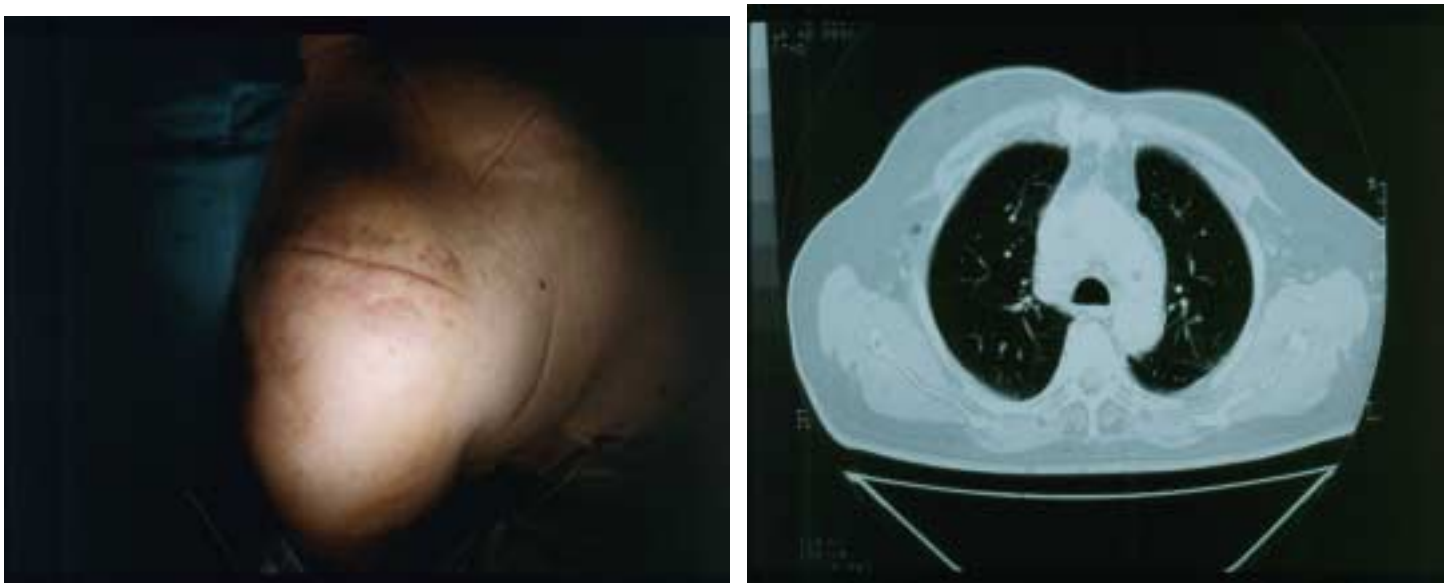

a b

Fig. 17 - a) Scapular metastases: the incision scar is from previous exploratory biopsy (the scapular localization was the first manifestation of disease); b) Lung metastases: the patient had undergone surgery for presumably benign "follicular adenoma" 10 years earlier (see description in text).

Medullary thyroid carcinoma

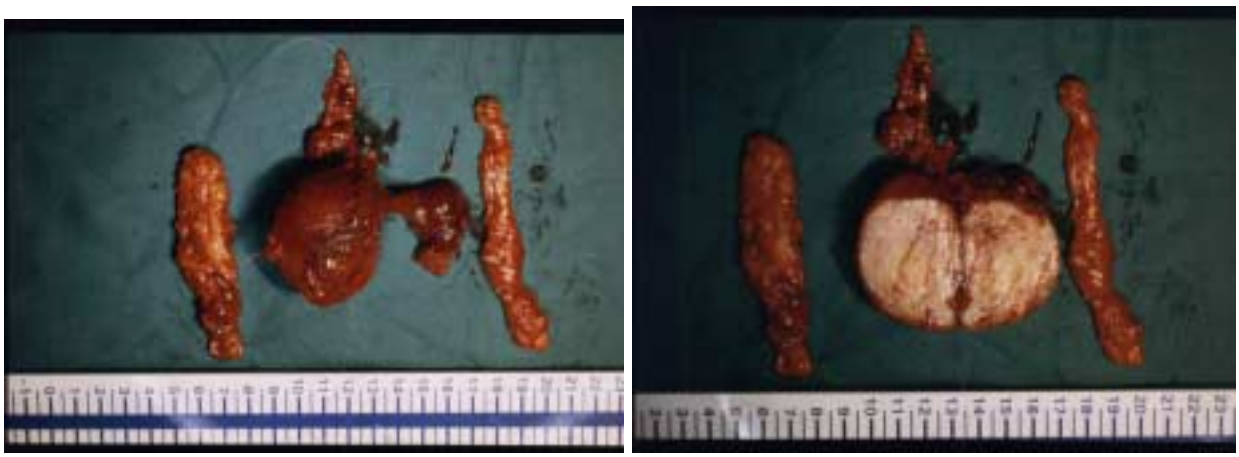

Fig. 18 - Medullary carcinoma. The specimen: the gland with the tumor and the lymphatic chain.

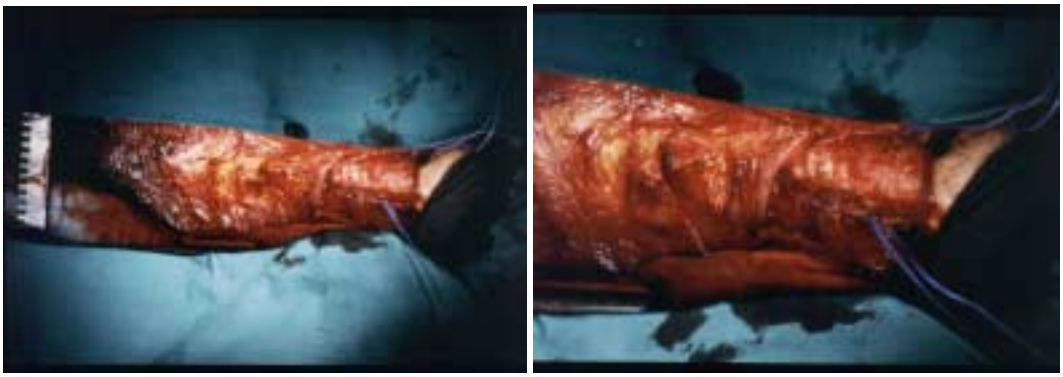

Fig. 19 - Sternotomic removal of mediastinal relapse following previous thyroidectomy.

Fig. 20 - Hepatic metastases from medullary carcinoma.